

## Spinal epidural capillary hemangioma: case report and review of the literature

Fabio Cofano, Nicola Marengo, Federico Pecoraro, Federica Penner, Luca Bertero & Francesco Zenga

To cite this article: Fabio Cofano, Nicola Marengo, Federico Pecoraro, Federica Penner, Luca Bertero & Francesco Zenga (2019): Spinal epidural capillary hemangioma: case report and review of the literature, *British Journal of Neurosurgery*, DOI: [10.1080/02688697.2018.1562034](https://doi.org/10.1080/02688697.2018.1562034)

To link to this article: <https://doi.org/10.1080/02688697.2018.1562034>



Published online: 04 Mar 2019.

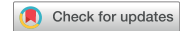

Submit your article to this journal [↗](#)



View Crossmark data [↗](#)

REPORT



## Spinal epidural capillary hemangioma: case report and review of the literature

Fabio Cofano<sup>a</sup>, Nicola Marengo<sup>a</sup>, Federico Pecoraro<sup>b</sup>, Federica Penner<sup>a</sup>, Luca Bertero<sup>c</sup>  and Francesco Zenga<sup>a</sup>

<sup>a</sup>Department of Neuroscience, Neurosurgery, AOU Città della Salute e della Scienza di Torino, Turin, Italy; <sup>b</sup>Spinal Surgery, Humanitas Research Center – Humanitas Gavazzeni, Bergamo, Italy; <sup>c</sup>Department of Medical Sciences, Pathology Division, AOU Città della Salute e della Scienza, Turin, Italy

### ABSTRACT

**Background:** Almost all of the epidural hemangiomas reported are cavernous hemangiomas. Purely extradural spinal capillary hemangiomas are very rare. Capillary hemangiomas are hamartomatous malformations that result from proliferations of vascular endothelial cells. Only ten cases have been reported in the English literature, treated with surgical excision.

**Case description:** A case of a dorsal extradural spinal capillary hemangioma is described. A total surgical removal has been performed after spinal angiography and embolization. Complete surgical removal should always be the goal in these lesions. Embolization did not show to reduce bleeding during the surgical procedure in this case.

### ARTICLE HISTORY

Received 25 June 2018  
Accepted 18 December 2018

### KEYWORDS

extradural hemangiomas;  
capillary hemangiomas;  
spine vascular lesions;  
pre-operative embolization;  
laminoplasty;

### Introduction

Vascular lesions of the spine are uncommon pathologies, mostly challenging to treat especially for surgeons. Among them, purely extradural hemangiomas are unusual. Generally, most exclusively epidural hemangiomas reported are cavernous hemangiomas.<sup>1–4</sup> Hasan *et al.* reported that cavernous hemangiomas were found in 11% of spines on autopsy.<sup>5</sup>

Conversely, purely extradural spinal capillary hemangiomas are very rare. Capillary hemangiomas are ubiquitous hamartomatous malformations that result from proliferations of vascular endothelial cells.<sup>6</sup> Only ten cases have been reported in the English literature,<sup>7</sup> and among them only a case has occurred in childhood.<sup>8</sup>

In this report we described a case of a dorsal extradural spinal capillary hemangioma and reviewed the literature. This work has been reported in line with the SCARE criteria.<sup>9</sup>

### Case presentation

This is a case of a 52-years-old woman. In her past history she referred psoriasis and removal of a benign breast tumor. During the last 5 years a subtle misdiagnosed onset of a pareto-spastic gait occurred, until the situation progressively significantly impaired her quality of life. Then a Magnetic Resonance Imaging (MRI) of the cervico-dorso-lumbar spine showed an epidural lesion at the level of D6-D9 with extension into the left D7 foramen (Figure 1). Significantly flow voids was seen on T2, indicating the probably highly vascular origin of the lesion. The lesion enhanced intensely. Spinal cord was severely dislocated anteriorly, with hyperintense cord signal as a sign of myelopathy.

On neurological examination, she had bilateral lower limbs weakness ranging from 3/5 proximally to 4-/5 distally. She had hypoesthesia of light touch from D7 level, but not of temperature.

68 Her gait was wide based. She complained urinary incontinence and dorsalgia. Babinski sign was observed bilaterally. Clonus was observed at left. Her reflexes were exaggerated at lower limbs. She was not able to walk autonomously.

The patient underwent a CT scan that showed that there was no bone involvement of vertebrae. The case was discussed between neurosurgeons and neuroradiologists. Because of the high suspect of a vascular origin of the lesion, the patient underwent a spinal angiography. The target was to better understand the nature of the lesion and, if possible, to investigate the possibility of a preliminary treatment before surgical procedure. The catheterism showed the presence of an abundant pathological circulation fed by the left D6 intercostal artery. The branch involved in the supply of the lesion was occluded with polyvinyl alcohol particles, obtaining a complete radiological devascularization (Figure 2). The following day the patient underwent surgical procedure. A D6-D9 laminotomy with ultrasonic aspirator and following laminoplasty was performed (Figure 3(A)). The lesion appeared as a reddish epidural mass that was resected en bloc. It was soft and hemorrhagic despite the embolization (Figure 3(B)).

Postoperatively she rapidly improved and was able to walk autonomously after two weeks. Twelve months after rehabilitation she referred no more dorsalgia and improvement of sphincter control. Only residual hypoesthesia remained. Histopathology analysis revealed the final diagnosis: capillary hemangioma (Figure 4(A) and (B)).

### Discussion

Capillary hemangiomas are composed of vascular endothelial cells and belonged to a group of hamartomatous lesions classified

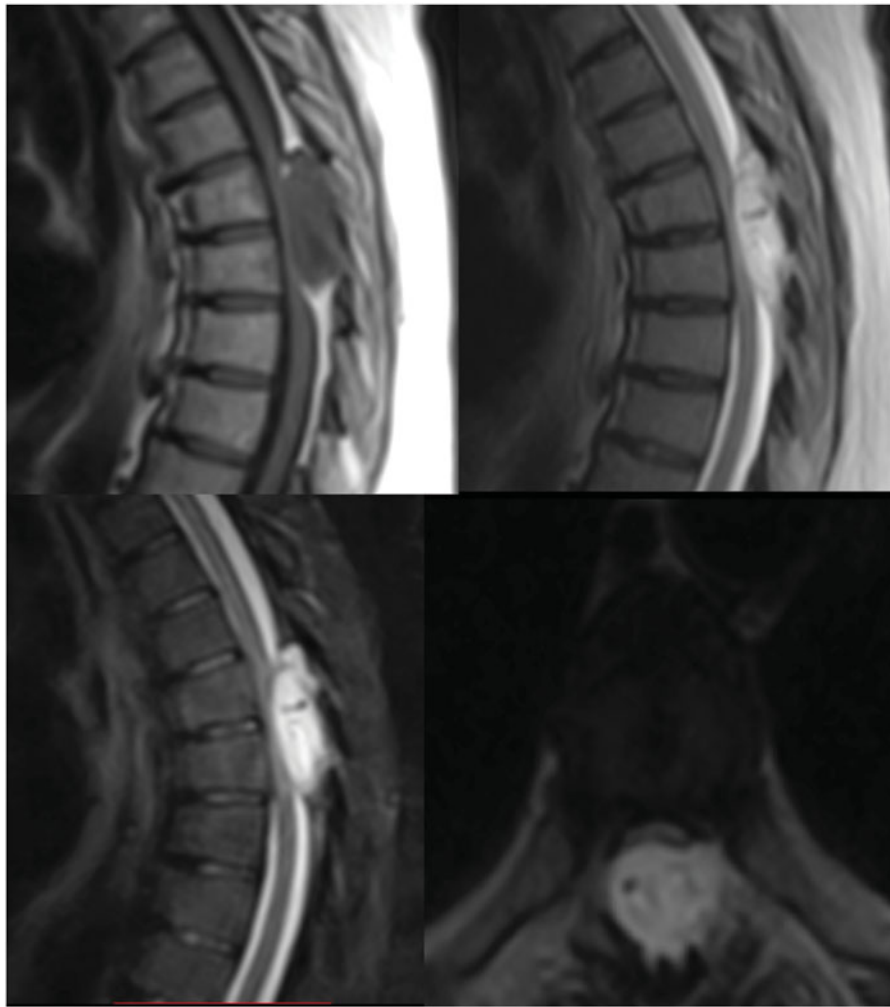


Figure 1. MRI appearance of an epidural capillary hemangioma: hypointense on T1-weighted, hyperintense on T2 weighted and enhancement with gadolinium.

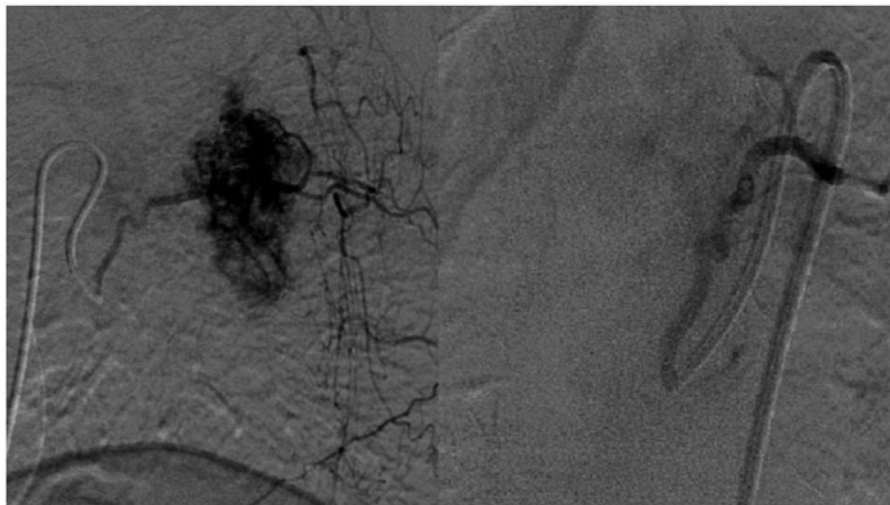


Figure 2. Angiogram of the lesion, before (left) and after (right) the embolization with radiological disappearance of its vascular pattern. Nevertheless bleeding during surgery was remarkable.

according to the predominant type of vascular channel observed histologically: capillary, cavernous, arterio-venous or venous.<sup>8</sup>

Among them, most exclusively epidural hemangiomas described in literature were cavernous hemangiomas.<sup>1,3</sup>

Histologically, cavernous malformations showed a large number of sinusoidal channels spread in collagenous tissue.<sup>3</sup> On the contrary, capillary hemangiomas are composed of thin and irregular capillary sized vessels in a low attenuating fibrosis and lobular

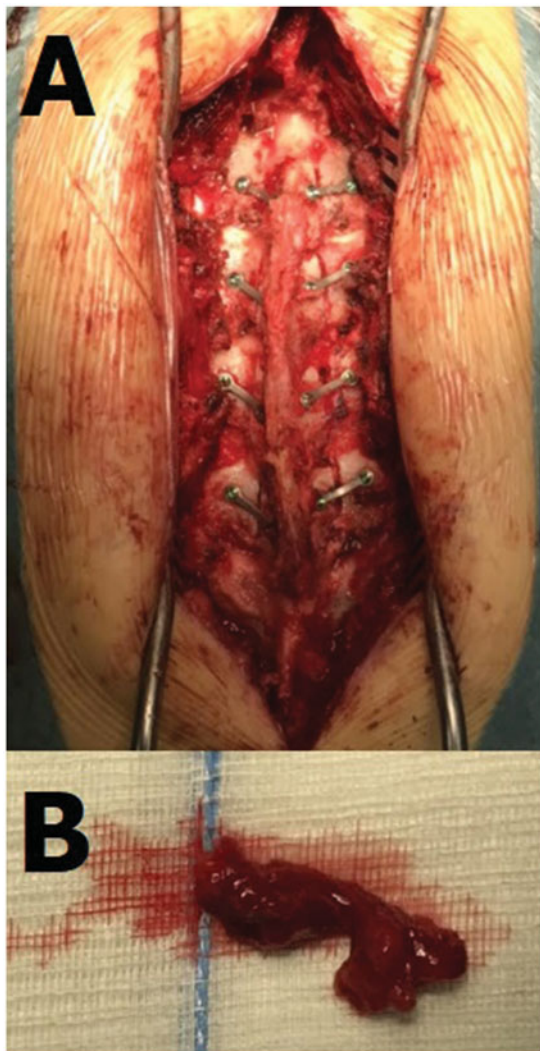

Figure 3. (A) Laminoplasty after hemangioma removal. (B) The lesion resected en bloc.

architecture.<sup>10,11</sup> Moreover, they showed low mitotic activity, positive reactions for CD31 and CD34, negative reactions for S100 and epithelial membrane antigen.<sup>1</sup>

In the literature, only ten cases of purely epidural capillary hemangioma have been reported (Table 1). Among them, there is only a case presented in childhood. The others occurred in adults over the age of 40. Of these capillary hemangiomas, seven were in the thoracic region and two in the lumbar region.

Generally, central nervous system cavernous hemangiomas can show sign of hemorrhages of various ages.<sup>8</sup> Epidural hemangiomas, on the contrary, present usually with compressive myelopathy or radicular pain – depending on the localization – and back pain. There are some reports showing hemorrhagic presentations of cavernous epidural hemangiomas,<sup>3</sup> but in none of the cases of capillary hemangiomas described there was sign of previous hemorrhage. In our case, actually, the patient clinically presented with progressive paraparesis, sphincteric incontinence and dorsalgia due to mechanical compression, misdiagnosed for 5 years.

The most important diagnostic exam is without any doubt the MRI, although radiologic aspects are non-specific. These lesions are generally well-circumscribed and a dumbbell shape can be

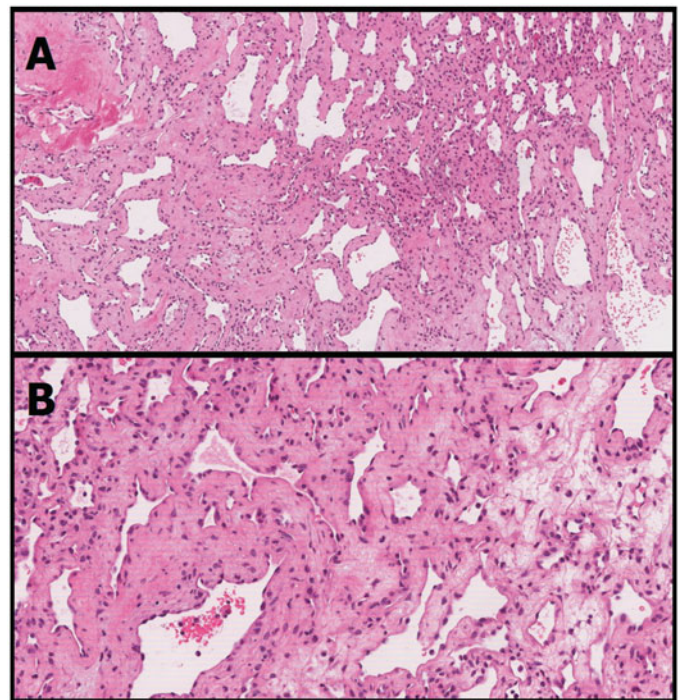


Figure 4. (A) Low power (100×) image showing the lobular architecture with numerous capillary sized vessels in the monotonous hypocellular fibrous stroma. (B) Medium power (200×) image showing the single layer of benign flattened endothelial cells.

observed, though this could be also an imaging pattern of tumors like meningiomas and neuromas.<sup>8</sup>

If surgeon has not an acute compression to deal with, an angiography is recommended. In this case, actually, because of the long duration of neurological history, the patient underwent a medullary angiography. After consultation with neuroradiologists, the lesion was embolized trying to avoid an exceeding bleeding during the following surgical procedure. The lesion was completely removed en bloc. There are no reports describing pre-operative embolization in extradural capillary hemangiomas. Despite the treatment, bleeding during surgery was remarkable and embolization did not bring any advantage. Thus some considerations could be made: a radiological embolization of the feeder, or its early surgical cauterization, as for artero-venous malformations of brain and spine does not necessarily results in a devascularization because of compensatory collateral circulation. Moreover, it could potentially worsen the compression in the spinal canal. Finally, it is a procedure that carries its own potential risks and morbidity.

A laminoplasty was performed: the cervical canal was opened with a bilateral laminotomy by using an ultrasonic dissector. Laminoplasty was preferred in order to obtain a clear exposure of the spinal canal, to better protect the spinal cord after the excision and to allow a following stabilization with screws if necessary. The treatment of choice for capillary hemangiomas is a complete surgical removal, as total resection is the cure of this benign lesion, although it could be difficult to achieve in its frequent foraminal extension.

Some authors recommend that surgery should be performed even in the absence of neurological symptoms if there is a cord compression on MRI, or at least a close follow-up.<sup>7</sup> The prognosis after complete removal is typically good and no relapses have been reported.

Table 1. Review of the literature.

Case	Age	Symptoms	Location	Treatment
1) Gupta <i>et al.</i> <sup>12</sup>	50	Paraparesis	D8-D10	Total resection
2) Badinand <i>et al.</i> <sup>3</sup>	40	Paraparesis, dorsal pain	D2-D4	Total resection
3) Kang <i>et al.</i> <sup>13</sup>	56	Dorsal Pain	D3-D4	Decompression
4) Tekin <i>et al.</i> <sup>14</sup>	56	Lumbar back pain and L4 hypoesthesia	L3	Total resection
5) Hasan <i>et al.</i> <sup>7</sup>	57	Pain, monoparesis, sphincters involvement	D10-D12	Decompression
6) Vassal <i>et al.</i> <sup>15</sup>	59	Dorsal back pain, intercostal neuralgia, ataxia, paraparesis	D5-D7	Total resection
7) Seferi <i>et al.</i> <sup>16</sup>	58	Dorsal pain, paraparesis	D2-D4	Total resection
8) Gencpinar <i>et al.</i> <sup>6</sup>	1	Paraparesis	D3-D7	Total resection
9) Egu <i>et al.</i> <sup>17</sup>	60	L5 Lumbosciatlagia	L5-S1	Total resection
10) Rajeev <i>et al.</i> <sup>18</sup>	50	Paraparesis	L1-L2	Total resection
11) Cofano <i>et al.</i> 2018 (our case)	52	Dorsal pain, paraparesis, urinary incontinence, ataxia	D6-D9	Total resection

## Conclusion

Capillary Hemangiomas are very rare in their purely extradural localization. Neurological symptoms are due to mechanical compression. MRI is the imaging tool of choice. Medullary angiography can usually confirm the vascular origin of the lesion. Embolization did not show to reduce bleeding during the surgical procedure in the case described. Complete surgical removal should be the goal.

The patient has consented the submission of this case report to the journal.

The corresponding author certifies that there is no actual or potential conflict of interest in relation to this article.

## ORCID

Luca Bertero  <http://orcid.org/0000-0001-9887-7668>

## References

- Agha RA, Fowler AJ, Saetta A, Barai I, Rajmohan S, Orgill DP. A protocol for the development of reporting criteria for surgical case reports: the SCARE statement. *Int J Surg* 2016;27:187–9.
- Aoyagi N, Kojima K, Kasai H. Review of spinal epidural cavernous hemangioma. *Neurol Med Chir (Tokyo)* 2003;43:471–6.
- Badinand B, Morel C, Kopp N, Tran Min VA, Cotton F. Dumbbell-shaped epidural capillary hemangioma. *AJNR Am J Neuroradiol* 2003;24:190–2.
- Caruso G, Galarza M, Borghesi I, Pozzati E, Vitale M. Acute presentation of spinal epidural cavernous angioma: case report. *Neurosurgery* 2007;60:E575–6.
- Equ K, Kinata-Bambino S, Mounadi M, *et al.* Lumbosacral epidural capillary hemangioma mimicking a dumbbell-shaped neurinoma: a case report and review of the literature. *Neurochirurgie* 2016;62:113–7.
- Gencpinar P, Açıkbaş SC, Nur BG, *et al.* Epidural capillary hemangioma: a review of the literature. *Clin Neurol Neurosurg* 2014;126:99–102.
- Hasan A, Guiot M, Torres C, Marcoux J. A case of a spinal epidural capillary hemangioma: case report. *Neurosurgery* 2011;68:E850–3.
- Jo BJ, Lee SH, Chung SE, *et al.* Pure epidural cavernous hemangioma of the cervical spine that presented with an acute sensory deficit caused by hemorrhage. *Yonsei Med J* 2006;47:877–80.
- Murphey MD, Fairbairn KJ, Parman LM, Baxter KG, Parsa MB, Smith WS. From the archives of the AFIP. Musculoskeletal angiomatous lesions: radiologic-pathologic correlation. *Radiographics* 1995;15:893–917.
- Nowak DA, Widenka DC. Spinal intradural capillary haemangioma: a review. *Eur Spine J* 2001;10:464–72.
- Shin JH, Lee HK, Jeon SR, Park SH. Spinal intradural capillary hemangioma: MR findings. *AJNR Am J Neuroradiol* 2000;21:954–6.
- Gupta S, Kumar S, Banerji D, *et al.* Magnetic resonance imaging features of an epidural spinal haemangioma. *Australasian Radiology* 1996;40:342–4.
- Kang JS, Lillehei KO, Kleinschmidt-Demasters BK. Proximal nerve root capillary hemangioma presenting as a lung mass with bandlike chest pain: case report and review of literature. *Surg Neurol* 2006;65:584–9.
- Tekin T, Bayrakli F, Simsek H, *et al.* Lumbar epidural capillary hemangioma presenting as a lumbar disc herniation disease: case report. *Spine* 2008;33(21):E795–7.
- Vassal F, Péoc'h M, Nuti C. Epidural capillary hemangioma of the thoracic spine with proximal nerve root involvement and extraforaminal extension. *Acta Neurochir* 2011;153:2279–81.
- Seferi A, Alimehmeti, Vyshka G, *et al.* Case study of a spinal epidural capillary hemangioma: a 4-year postoperative follow-up. *Global Spine J.* 2014;4(1):55–58.
- Egu K, Kinata-Bambino S, Mounadi M, *et al.* Lumbosacral epidural capillary hemangioma mimicking a dumbbell-shaped neurinoma: a case report and review of the literature. *Neurochirurgie*. 2016;62(2):113–7.
- Rajeev MP, Waykule PY, Pavitharan VM, *et al.* Spinal epidural capillary hemangioma: a rare case report with a review of literature. *Surg Neurol Int.* 2017;8:123.